

2016

Epigenetic Modification Prevents Excessive Wound Healing and Scar Formation After Glaucoma Filtration Surgery

Ajay Sharma

Chapman University, sharma@chapman.edu

Govindaraj Anumanthan

Harry S. Truman Memorial Veterans' Hospital

Marcos Reyes

Harry S. Truman Memorial Veterans' Hospital

Huiyi Chen

Harry S. Truman Memorial Veterans' Hospital

Jason W. Brubaker

*Harry S. Truman Memorial Veterans' Hospital**See next page for additional authors*Follow this and additional works at: https://digitalcommons.chapman.edu/pharmacy_articles

Part of the [Animal Experimentation and Research Commons](#), [Animals Commons](#), [Musculoskeletal, Neural, and Ocular Physiology Commons](#), [Ophthalmology Commons](#), and the [Other Pharmacy and Pharmaceutical Sciences Commons](#)

Recommended Citation

Sharma A, Anumanthan G, Reyes M, et al. Epigenetic Modification Prevents Excessive Wound Healing and Scar Formation After Glaucoma Filtration Surgery. *Invest Ophthalmol Vis Sci.* 2016;57(7):3381-3389. doi:10.1167/iovs.15-18750.

This Article is brought to you for free and open access by the School of Pharmacy at Chapman University Digital Commons. It has been accepted for inclusion in Pharmacy Faculty Articles and Research by an authorized administrator of Chapman University Digital Commons. For more information, please contact laughtin@chapman.edu.

Epigenetic Modification Prevents Excessive Wound Healing and Scar Formation After Glaucoma Filtration Surgery

Comments

This article was originally published in *Investigative Ophthalmology & Visual Science*, volume 57, issue 7, in 2016. DOI: [10.1167/iovs.15-18750](https://doi.org/10.1167/iovs.15-18750)

Creative Commons License



This work is licensed under a [Creative Commons Attribution-Noncommercial-No Derivative Works 4.0 License](https://creativecommons.org/licenses/by-nc-nd/4.0/).

Copyright

Association for Research in Vision and Ophthalmology

Authors

Ajay Sharma, Govindaraj Anumanthan, Marcos Reyes, Huiyi Chen, Jason W. Brubaker, Saad Siddiqui, Suneel Gupta, Frank G. Rieger, and Rajiv R. Mohan

Epigenetic Modification Prevents Excessive Wound Healing and Scar Formation After Glaucoma Filtration Surgery

Ajay Sharma,^{1,2} Govindaraj Anumanthan,^{1,2} Marcos Reyes,^{1,3} Huiyi Chen,^{1,3} Jacob W. Brubaker,^{1,3} Saad Siddiqui,^{1,2} Suneel Gupta,^{1,2} Frank G. Rieger,^{1,3} and Rajiv R. Mohan¹⁻³

¹Harry S. Truman Memorial Veterans' Hospital, Columbia, Missouri, United States

²One-Health One-Medicine Ophthalmology and Vision Research Center, College of Veterinary Medicine, University of Missouri, Columbia, Missouri, United States

³Mason Eye Institute, School of Medicine, University of Missouri, Columbia, Missouri, United States

Correspondence: Rajiv R. Mohan, University of Missouri, 1600 E. Rollins Road, Columbia, MO 65211, USA; mohanr@health.missouri.edu.

AS and MR contributed equally to the work presented here and should therefore be regarded as equivalent authors.

Submitted: November 26, 2015

Accepted: March 28, 2016

Citation: Sharma A, Anumanthan G, Reyes M, et al. Epigenetic modification prevents excessive wound healing and scar formation after glaucoma filtration surgery. *Invest Ophthalmol Vis Sci.* 2016;57:3381-3389.

DOI:10.1167/iovs.15-18750

PURPOSE. The purpose of this study was to determine the efficacy of suberoylanilide hydroxamic acid (SAHA), a histone deacetylase inhibitor (HDACi), in prevention of excessive wound healing and scar formation in a rabbit model of glaucoma filtration surgery (GFS).

METHODS. A rabbit model of GFS was used. Rabbits that underwent GFS received balanced salt solution, or SAHA (50 μ M), or mitomycin C (0.02%). Clinical scores of IOP, bleb vascularity, and slit-lamp examination were performed. On postoperative day 14, rabbits were killed and the bleb tissues were collected for evaluation of tissue fibrosis with hematoxylin and eosin, Masson trichrome, α -smooth muscle actin (α SMA), and F-actin staining. Furthermore, SAHA-mediated acetylation of histones in corneal fibroblasts and conjunctiva were determined by Western blot analysis.

RESULTS. Suberoylanilide hydroxamic acid treatment after GFS showed no signs of edema, corneal opacity, endophthalmitis, or cataract formation. Morphometric analysis of SAHA-treated eyes showed higher bleb length ($P < 0.001$), bleb area ($P < 0.05$), lower IOP ($P < 0.01$), and decreased vascularity compared to control. Furthermore, SAHA treatment showed significantly reduced levels of α SMA ($P < 0.001$), F-actin ($P < 0.01$), and collagen deposition ($P < 0.05$) at the sclerotomy site. In addition, SAHA treatment increased the acetylation status of H3 and H4 histones in corneal fibroblasts and conjunctiva.

CONCLUSIONS. This study demonstrates that HDAC inhibition is an attractive pharmacologic target to modulate GFS wound healing, and SAHA, an HDACi, can be a useful adjunct to improve the GFS outcome.

Keywords: glaucoma anterior segment, SAHA, fibrosis, wound healing

Glaucoma is the second leading cause of blindness according to the World Health Organization.¹ In the United States alone, glaucoma affects approximately 2.2 million people.² The major goal of glaucoma therapy is to reduce IOP to levels considered safe for the optic nerve to preserve visual function. Currently, several topical drugs capable of reducing intraocular pressure are used for glaucoma treatment.³ However, a large number of patients do not respond adequately to topical drug therapy to reduce IOP. The most preferred treatment for such patients is glaucoma filtration surgery (GFS). A major deterrent to the success of GFS is caused by aberrant postoperative wound healing resulting in excessive extracellular matrix (ECM) synthesis, which leads to fibrosis over filtering bleb.⁴⁻⁷ Development of fibrosis and collagen deposit at the sclerotomy site compromises bleb's proper functioning and disables its ability to maintain nonpathologic reduced IOP. To prevent this common complication, cytotoxic drugs such as mitomycin C (MMC) and 5-fluorouracil are frequently utilized intraoperatively and in clinical practice to reduce scar formation caused by GFS.⁸⁻¹⁰ Though these drugs are effective in preventing ocular fibrosis and improving the

outcome of filtration surgery, they are known to cause sight-threatening complications, including widespread cell death, bleb leak, hypotony, and/or endophthalmitis.¹¹⁻¹⁵ Thus, drugs that do not cause intense wound healing and can effectively prevent bleb fibrosis without significant side effects are needed for glaucoma management.

Glaucoma filtration surgery initiates a cascade of events including blood exudation, fibrin deposit, recruitment of inflammatory cells, and release of cytokines/growth factors.^{4-7,16,17} The released cytokines alter the gene expression of proliferative, cytoskeletal, and matrix proteins, thus leading to fibrosis.¹⁸ Epigenetic regulations play a critical role, which comprises regulation of gene expression by methylation/acetylation of DNA and histone proteins. Histone acetylation regulates gene expression by altering DNA structure, thus influencing DNA binding to various transcription factors.^{19,20} Histone deacetylase inhibitors (HDACis) represent a new class of pharmacologic agents that can modulate gene expression by increasing histone acetylation. Histone deacetylase inhibitors are shown to have pleiotropic antifibrotic effect in vivo in a wide variety of animal models of skin, liver, lung, and heart

fibrosis.^{21–28} Although several HDACis are at various stages of preclinical and clinical development, suberoylanilide hydroxamic acid (SAHA) (vorinostat) is the only HDACi currently approved by the U.S. Food and Drug Administration (FDA) for use in human patients. We recently demonstrated the antifibrotic effect of SAHA on laser surgery-induced corneal scarring *in vivo*.^{29,30} Unlike other antifibrotic agents, SAHA is relatively nontoxic and does not affect the viability or proliferation of corneal fibroblasts.^{29–32} Given the potent antifibrotic effect of SAHA and its relative lack of toxicity to normal cells, we hypothesized that SAHA may represent a prospective therapeutic agent to attenuate postoperative fibrosis after filtration surgery. Therefore, the present study was designed to test the antifibrotic efficacy of SAHA (FDA-approved HDACi) in a rabbit model of GFS.

MATERIALS AND METHODS

Glaucoma Filtration Surgery in Rabbits

Female New Zealand white rabbits were used in the study. The Institutional Animal Care and Use Committee (ACUC) of the University of Missouri-Columbia and Harry S. Truman Memorial Veterans' Hospital approved the study. All animals were treated in accordance with the ARVO Statement for the Use of Animals in Ophthalmic and Vision Research. The rabbits were anesthetized by intramuscular injection of a mixture of ketamine hydrochloride (50 mg/kg) and xylazine hydrochloride (10 mg/kg). In addition, topical ophthalmic 0.5% proparacaine hydrochloride (Alcon, Fort Worth, TX, USA) was used for local anesthesia. A partial-thickness corneal traction suture (6-0 silk) was placed in the superior cornea to rotate the eye inferiorly. A superior fornix-based conjunctival flap was created. The anterior chamber was entered using a Beaver blade, and a 1.5 × 1.5 mm full-thickness sclerotome was created using the blade. A peripheral iridectomy was performed. The conjunctival incision was closed with 10-0 nylon suture. Neomycin, polymyxin B sulfates, bacitracin zinc, and hydrocortisone ointment was applied at the end of the surgery and then once daily for 1 week after the surgery.

Preparation of SAHA Solution and Treatment Regimen

A 10-mM stock solution of SAHA (Cayman Chemical Company, Ann Arbor, MI, USA) was prepared by dissolving in dimethyl sulfoxide (DMSO) and then further diluted to 50 μ M with balanced salt solution (BSS) eye drops (Alcon). For vehicle control, the same volume of DMSO was diluted with BSS. The 0.04% MMC stock solution was prepared in BSS and a 0.02% final dose of MMC was given to rabbits. The rabbits were divided into three treatment groups. Group I rabbits received 100 μ L subconjunctival injection of vehicle 30 minutes before the GFS surgery, and group II rabbits received 100 μ L subconjunctival injection of 50 μ M SAHA solution 30 minutes before GFS. Group III rabbits were injected with 100 μ L subconjunctival solution of 0.02% MMC 30 minutes before surgery.

Clinical Evaluation

Clinical evaluation was performed to check the IOP, general appearance, and vascularity of the bleb. All these clinical parameters were recorded before the surgery to obtain the baseline values and on days 3, 5, 7, 10, and 14 after surgery. To measure IOP, tonometry was performed using an applanation tonometer (Tono-pen; Reichert Technologies, Depew, NY, USA) with animals under topical anesthesia. Bleb size was

graded by measuring its width and length. Bleb vascularity was graded as 0 = avascular; 1 = normal vascularity; 2 = hyperemic; 3 = very hyperemic. Anterior chamber inflammation was assessed by slit-lamp examination and graded 0 = no inflammation; 1 = cells present; 2 = fibrin formation; 3 = hypopyon present.

Histologic Evaluation

On postoperative day 14, rabbits were humanely euthanized with pentobarbital (150 mg/kg) under general anesthesia. The eyes were enucleated together with the conjunctiva to preserve the bleb and snap frozen in optimal cutting temperature fluid. The tissues were sectioned and stained with hematoxylin and eosin (H&E). Masson's trichrome staining was performed to stain collagen. Immunofluorescence staining for F-actin (a marker for activated fibroblasts and myofibroblasts) was performed using Alexa Fluor 594 conjugated phalloidin (1:40 dilution, A12381; Invitrogen, Inc., Carlsbad, CA, USA). Immunofluorescence staining for α -smooth muscle actin (α SMA), a marker for myofibroblasts, was performed with mouse monoclonal primary α SMA antibody (1:100 dilution, M0851; Dako, Carpinteria, CA, USA). Tissue sections were incubated with 2% bovine serum albumin for 30 minutes at room temperature and then with α SMA monoclonal antibody for 90 minutes. For detection of the primary antibody, the sections were exposed to Alexa 488 goat anti-mouse IgG secondary antibody (1:500 dilution, A11001; Invitrogen, Inc.) for 1 hour. The tissue sections at the site of sclerotomy and the sections on every sixth tissue slide on the either side of the sclerotomy were stained for F-actin and α SMA. After completion of immunostaining, tissue sections were mounted in medium containing DAPI (Vectashield; Vector Laboratories, Inc., Burlingame, CA, USA), viewed, and photographed under a fluorescence microscope (Leica Microsystems, Deerfield, IL, USA) equipped with a digital camera system (SpotCam RT KE; Diagnostic Instruments, Inc., Sterling, MI, USA). The stained areas in the imaged slides were quantified using Image J software (<http://imagej.nih.gov/ij/>); provided in the public domain by the National Institutes of Health, Bethesda, MD, USA).

Western Blot Analyses

Human corneal fibroblast cells were treated with or without SAHA (2.5 μ M) at different time intervals as indicated in figure legends. Rabbits received a 100- μ L subconjunctival injection of 50 μ M SAHA. Cell lysates were prepared from human corneal fibroblast cells treated with SAHA (2.5 μ M) at 0, 2, 4, 6, 16, and 24 hours. Rabbit conjunctival tissues were harvested at 0, 2, 6, and 24-hour time points. Cell and tissue lysates were analyzed by Western blotting using anti-acetyl histone H3, anti-acetyl histone H4 (Cell Signaling, Beverly, MA, USA), and β -actin (Santa Cruz Biotechnology, Inc., Dallas, TX, USA) antibodies respectively. All Western blots for each protein were used with three rabbit tissues and repeated at least two times. Digital quantification of Western blots was performed using Image J software (National Institutes of Health, Bethesda, MD, USA) and Image Studio software (Version 5.2, GraphPad Software, Inc., La Jolla, CA, USA).

Statistical Analysis

The results are expressed as mean \pm SEM. The data for bleb length, area, vascularity, and IOP were analyzed by 2-way ANOVA and Bonferroni test using GraphPad Prism 6.0 (GraphPad Software, Inc., La Jolla, CA, USA), and $P < 0.05$ was considered to be statistically significant. The immunostaining data were analyzed using a *t*-test.

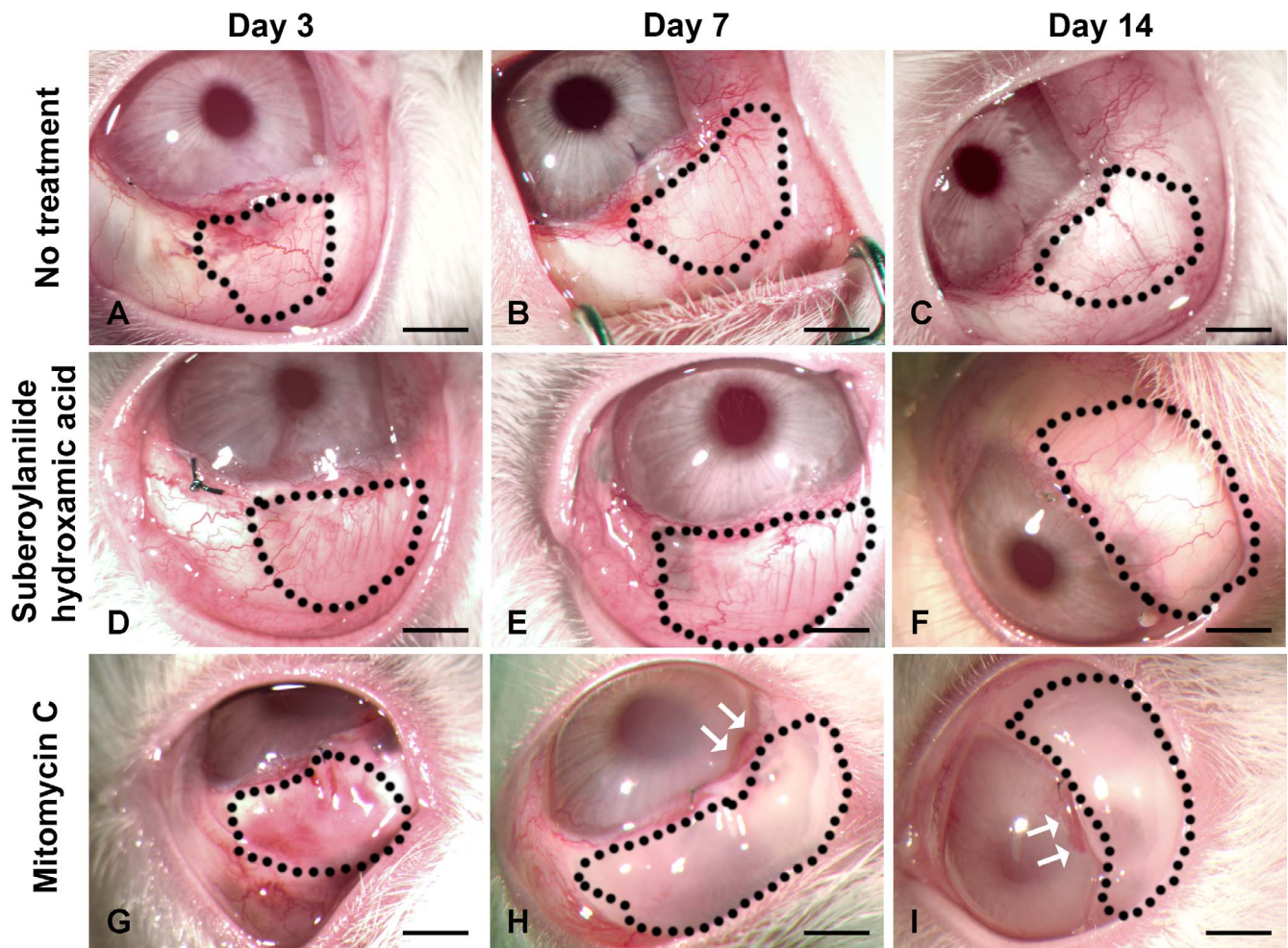


FIGURE 1. Suberoylanilide hydroxamic acid or MMC treatment improves bleb morphology after GFS. Representative stereomicroscopic images captured at day 3, 7, and 14 after GFS showing bleb characteristics in no-treatment control (A–C) and SAHA-treated (D–F) and MMC-treated (G–I) rabbit eyes. Suberoylanilide hydroxamic acid- or MMC-treated rabbit eyes showed bigger bleb area (outlined in black dotted lines). Scale bar: 3 mm.

RESULTS

Clinical Evaluation

The subconjunctival injection of SAHA was well tolerated and no signs of hyperemia or inflammation were detected at the site of injection. No sign of corneal edema, corneal opacity, endophthalmitis, or cataract were observed in any of the SAHA-treated rabbits. On the contrary, MMC-treated rabbit eyes showed corneal neovascularization and opacity (Figs. 1H, 1I).

Bleb Morphology and Characteristics

Biomicroscopy was performed on the rabbit eyes to monitor bleb characteristics. Figure 1 shows the typical appearance of blebs in no-treatment control (Figs. 1A–C), SAHA-treated (Figs. 1D–F), and MMC-treated (Figs. 1G–I) rabbits. Suberoylanilide hydroxamic acid-treated rabbit eyes showed transparent and elevated blebs (Figs. 1D–F) compared to flat and scarred blebs in no-treatment control rabbits (Figs. 1A–C). The MMC-treated rabbits also showed elevated blebs, but these blebs had a thin, avascular, and cystic appearance (Figs. 1G–I).

The morphometric analysis of the bleb length and area was performed using Vernier caliper and digital quantification of the acquired images. Figure 2 shows the mean bleb length (Fig. 2A) and bleb area (Fig. 2B) in no-treatment control and SAHA-

and MMC-treated rabbits at day 3, day 7, and day 14 after GFS. The SAHA-treated rabbit eyes showed significantly higher bleb area ($P < 0.05$) and length ($P < 0.001$) compared to untreated controls (Fig. 2). The MMC-treated rabbit eyes also showed significantly higher bleb area ($P < 0.01$) and length ($P < 0.001$) as compared to untreated controls. The relative comparison between SAHA- and MMC-treated groups demonstrated that MMC-treated rabbits had higher bleb area and length as compared to SAHA-treated rabbits, but the difference was not statistically significant.

Figure 3 shows vascularity scores of the blebs in no-treatment control and SAHA-treated and MMC-treated rabbits. The no-treatment control group showed increased vascularity in response to the surgical trauma. Suberoylanilide hydroxamic acid treatment significantly ($P < 0.01$) attenuated bleb vascularity on day 7 and day 14 after GFS. Mitomycin C treatment also caused a very robust decrease in bleb vascularity, and the effect was significantly more as compared to SAHA. By day 14, all the MMC-treated blebs were completely avascular and had a cystic appearance.

Intraocular Pressure

Figure 4 shows the effect of SAHA and MMC treatment on IOP in the rabbit eyes after GFS. As anticipated, there was a significant ($P < 0.01$) decrease in IOP in the no-treatment

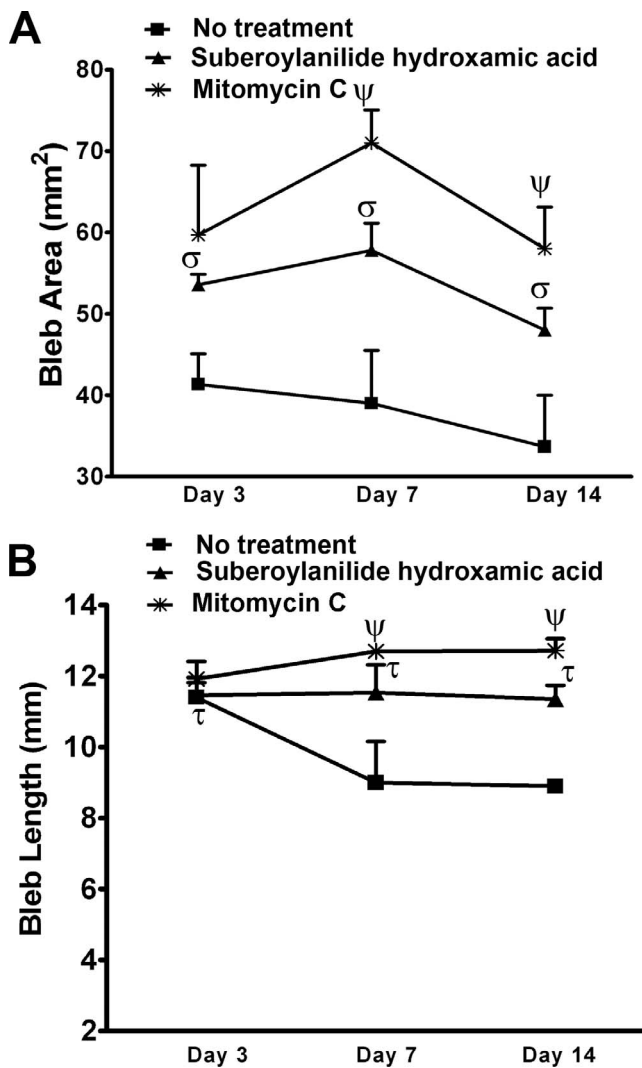


FIGURE 2. Quantitation of bleb area and length. Quantification of bleb length (A) and bleb area (B) at day 3, 7, and 14 after glaucoma filtration surgery in no-treatment control and SAHA- and MMC-treated rabbit eyes. Suberoylanilide hydroxamic acid- or MMC-treated rabbits showed significantly bigger blebs. $\sigma P < 0.05$, $\tau P < 0.01$, $\Psi P < 0.001$ compared to control. The Greek letter in *P* values indicate significance levels.

control and SAHA- and MMC-treated rabbits on day 3 after GFS as compared to the preoperative baseline values indicating successful surgery. However, by day 7 and day 14 the IOP started to increase in the untreated control group. On the contrary, SAHA- and MMC-treated rabbit showed lower IOP compared to the no-treatment control eyes, but the results were not statistically significant.

Histologic Evaluation

To evaluate whether SAHA treatment affected collagen deposition and myofibroblast formation after GFS, histologic staining and immunostaining were performed on the rabbit eye tissue sections. The H&E staining of the eye tissues obtained from no-treatment control rabbits (Fig. 5A) shows that the site of sclerotomy is densely packed with fibrous tissue. On the contrary, eye tissues of SAHA-treated rabbits (Fig. 5B) show mild fibrous deposit and a loosely arranged conjunctival tissue. Furthermore, Masson trichrome staining revealed fewer

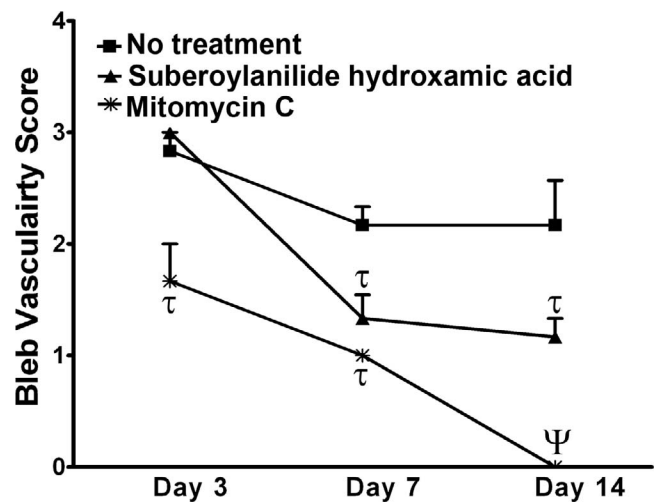


FIGURE 3. Suberoylanilide hydroxamic acid decreases bleb vascularity. Quantification of bleb vascularity at day 3, 7, and 14 after GFS in no-treatment control and SAHA- and MMC-treated rabbit eyes. Both SAHA and MMC significantly reduced the bleb vascularity. $\tau P < 0.01$ compared to control, $\Psi P < 0.001$ compared to control and SAHA.

collagen deposits at the site of sclerotomy in the SAHA-treated (Fig. 5D) tissues as compared to the eye tissue sections obtained from no-treatment control rabbits (Fig. 5C).

To determine the effect of SAHA treatment in acetylation status of histones, we performed Western blot analyses using human corneal fibroblast cells (Fig. 6A) and conjunctiva tissue (Fig. 6B) treated with SAHA at different time intervals. Suberoylanilide hydroxamic acid treatment increased the acetylation status of histone H3 and H4 and attained maximum at 6 hours and gradual decrease at 24 hours. Corresponding Western blot quantitation data are provided in Figures 6C through 6F. These data suggest that SAHA treatment effectively increases the acetylation status of histone H3 and H4, thereby regulating target gene expression or repression involved in excessive wound healing and scar formation.

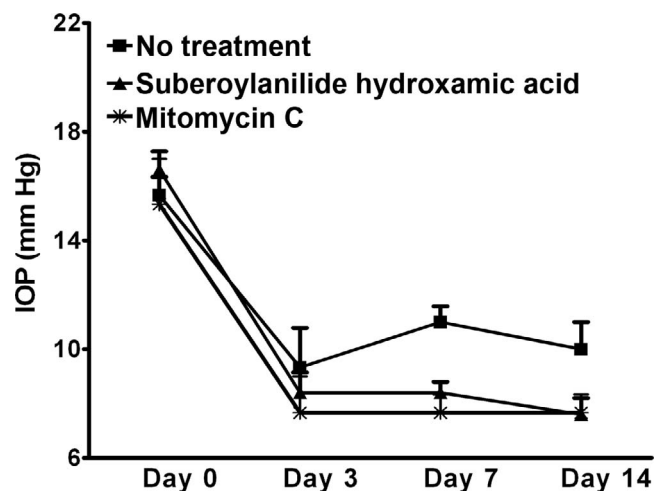


FIGURE 4. Suberoylanilide hydroxamic acid or MMC reduces IOP. Intraocular pressure measured at day 3, 7, and 14 after glaucoma filtration surgery in no-treatment control and SAHA- or MMC-treated rabbits. Suberoylanilide hydroxamic acid- or MMC-treated rabbit had lower IOP at day 7 and day 14 as compared to no-treatment control, but the decrease is not statistically significant.

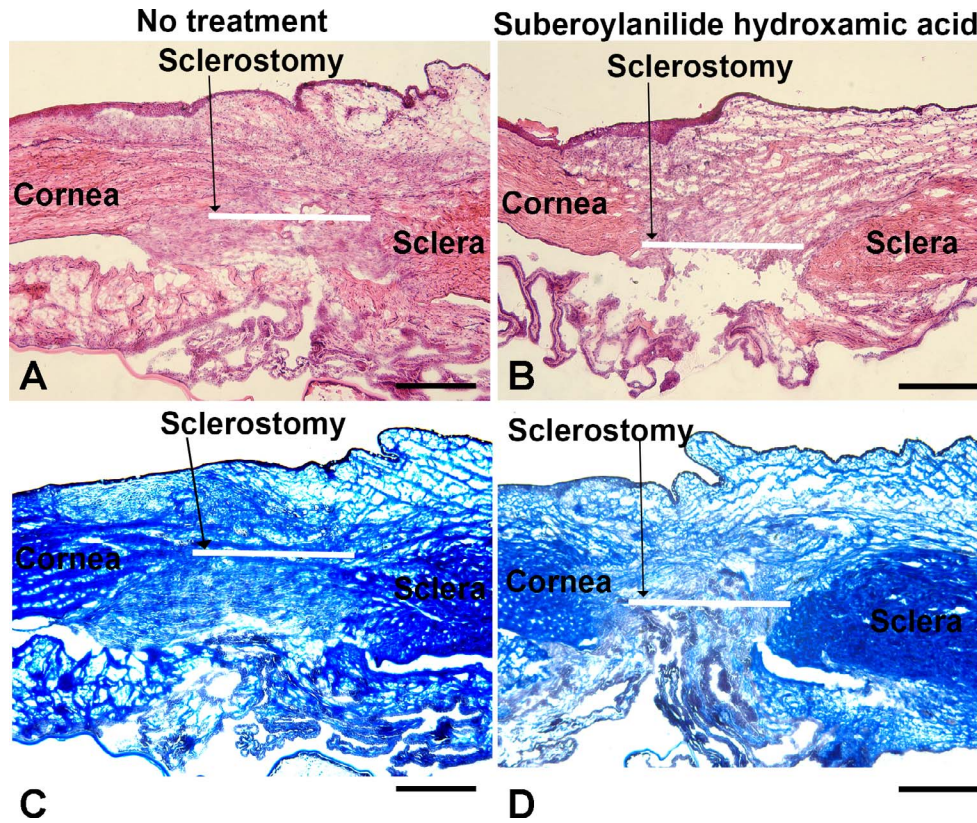


FIGURE 5. Suberoylanilide hydroxamic acid decreases collagen deposition at the site of GFS. Representative images showing H&E (A, B) and Masson's trichrome (C, D) staining in no-treatment control (A, C) and SAHA-treated (B, D) rabbit eyes. The tissues were collected at day 14 after the glaucoma filtration surgery. The H&E staining of SAHA-treated tissue sections (B) shows loosely arranged, less-fibrous conjunctival tissues, whereas no-treatment control tissues (A) are densely packed with fibrous deposit. Masson's trichrome staining shows prominent collagen deposit (blue color) in control tissues (C), whereas collagen deposit is notably decreased in SAHA-treated rabbit tissues (D). Scale bar: 400 μ m.

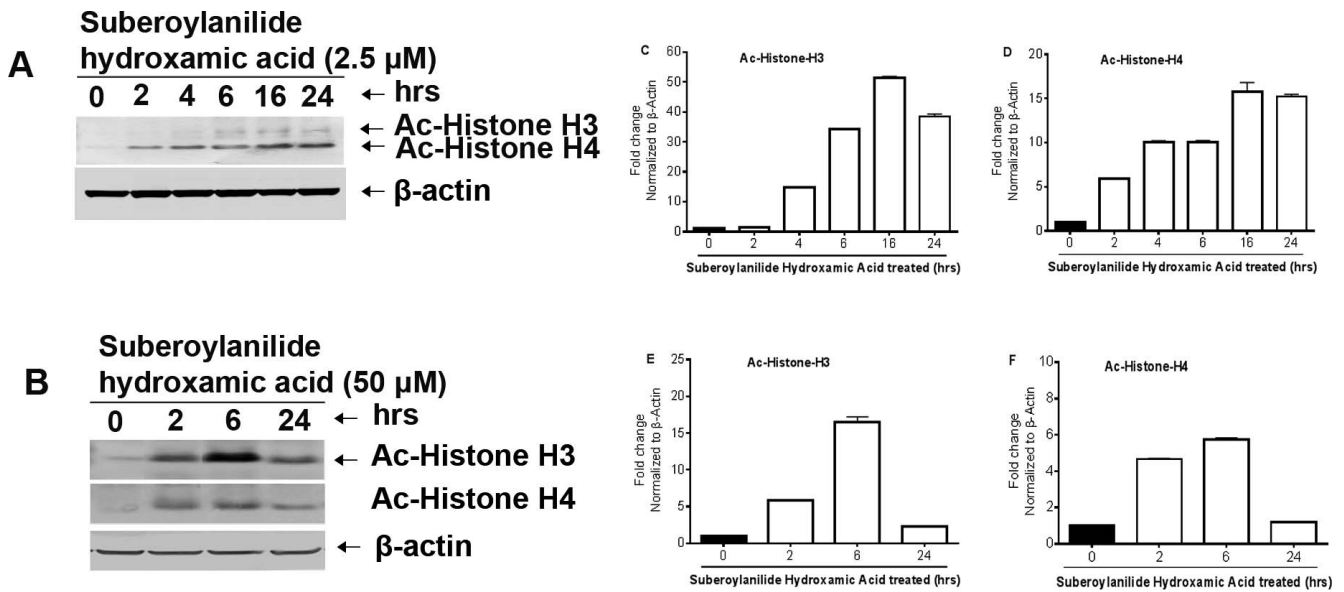


FIGURE 6. Suberoylanilide hydroxamic acid treatment increases acetylation of histones in human corneal fibroblasts and rabbit conjunctiva tissues. (A) Human corneal fibroblast cells treated with SAHA (2.5 μ M) for indicated times and (B) rabbit conjunctiva injected with SAHA (50 μ M) for indicated times were analyzed by Western blot using anti-Ac-histone H3, anti-Ac-histone H4, and anti- β -actin antibodies. Corresponding Western blot quantitative analysis data provided in C, D, E and F panels.

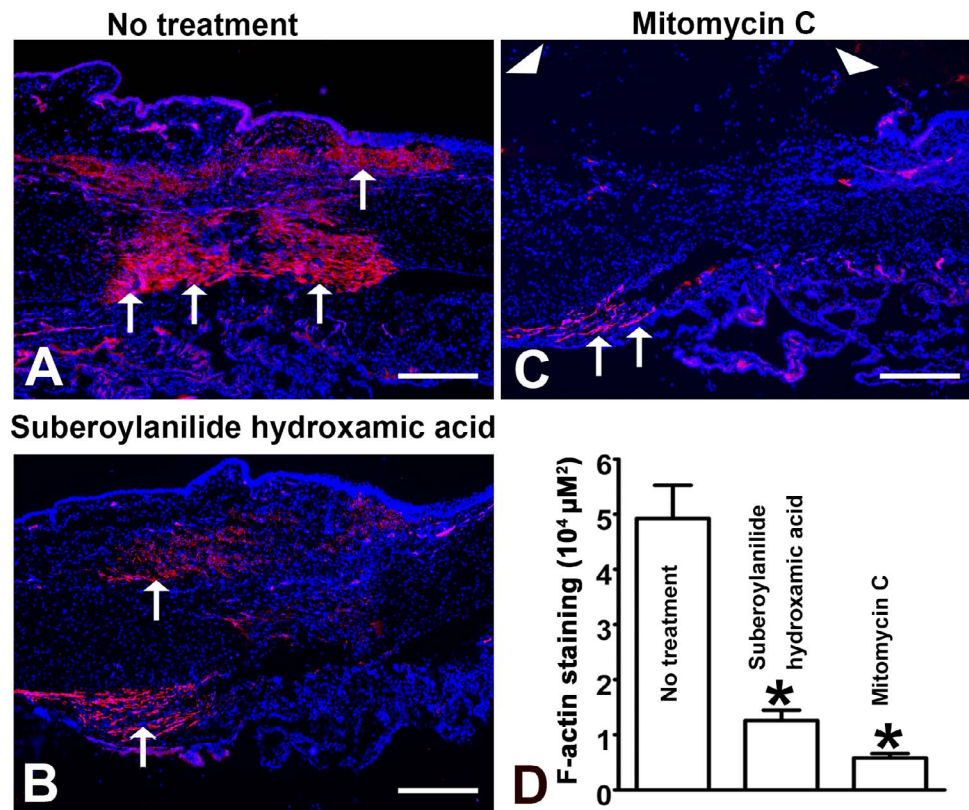


FIGURE 7. Suberoylanilide hydroxamic acid treatment decreases F-actin assembly. Representative images showing immunofluorescence staining for F-actin (marker for activated fibroblasts and myofibroblast) in no-treatment control (A) and SAHA-treated (B) and MMC-treated (C) rabbit ocular tissue sections. The tissues were collected at day 14 after the glaucoma filtration surgery. Nuclei are stained blue and F-actin is stained red (arrows). Scale bar: 200 μm. Graph (D) shows a significant ($*P < 0.01$) decrease in the F-actin-stained area in the SAHA- and MMC-treated rabbit tissues. Arrowhead shows discontinuous and highly sparse DAPI nuclear staining of the conjunctival epithelium in the MMC-treated rabbit tissue sections.

Presence of activated fibroblasts and myofibroblasts is a key feature of scarred bleb. Therefore, immunostaining for F-actin (a marker for activated fibroblasts and myofibroblasts) and α SMA (a marker for myofibroblasts) was performed to detect the changes in the pattern of these proteins.³³ Ocular tissue sections collected from no-treatment control rabbits showed intense F-actin (Fig. 7A) and α SMA (Fig. 8A) staining at the site of sclerostomy, in the subconjunctival space, and in the sclera. On the other hand, ocular tissues collected from SAHA-treated rabbit showed sparse F-actin (Fig. 7B) and α SMA (Fig. 8B) staining at the site of sclerostomy, in the subconjunctival space, and in the sclera. Morphometric quantification for F-actin and α SMA revealed that SAHA treatment caused a significant decrease in the F-actin-stained (Fig. 7D) and α SMA-stained (Fig. 8D) area ($P < 0.01$), thus confirming that the improved bleb characteristics in SAHA-treated rabbits is complemented by a decreased fibrosis and scarring at the site of sclerostomy.

As expected, MMC treatment also caused a very robust decrease in F-actin (Fig. 7C) and α SMA (Fig. 8C) staining. The morphometric quantification revealed that the MMC effect was significantly more as compared to SAHA. However, it should be noted that MMC treatment was associated with notable toxicity to the conjunctival epithelium. DAPI nuclear staining revealed (Figs. 7–8) a continuous and uniform conjunctival epithelium at the site of sclerostomy in no-treatment control and SAHA-treated rabbit tissue sections. On the other hand, MMC-treated rabbit tissue showed discontinuous and highly sparse DAPI nuclear staining for the conjunctival epithelium, thus suggesting a cytotoxic effect of MMC to the cells of conjunctival epithelium.

DISCUSSION

Glaucoma filtration surgery remains the mainstay procedure for the clinical management of drug-refractory glaucoma. Postoperative wound healing of the scleral flap and scarring of the overlying conjunctiva are the major impediments to surgical success of GFS.^{4–7} In the present study, we demonstrate that SAHA remarkably reduces postoperative scarring in the rabbit model of GFS. Bleb areas were consistently larger in the SAHA-treated groups, and it was corroborated by histologic findings showing decreased ECM deposit and collagen deposition. Several lines of evidence suggest that histone acetylation plays a role in transcriptional regulation, probably by altering chromatin structures. Chromatin fractions enriched in actively transcribed genes are also enriched in the more highly acetylated isoforms of the core histones. Suberoylanilide hydroxamic acid binds directly to the catalytic site of HDAC, inhibiting its deacetylase enzymatic activity.³⁴ Histone deacetylase inhibitors are an emerging group of drugs that can potentially regulate gene expression by altering the acetylation of chromatin and other nonhistone proteins.^{17,18} Initially developed as anticancer drugs, they are increasingly being shown to be effective in treating fibrosis.^{35,36} To our knowledge, this is the first study to demonstrate the beneficial effect of an HDACi on the outcome of GFS. Although the exact mechanism of their antifibrotic effect is not fully understood, several hypothesis have been proposed, including the suppression of profibrotic genes such as *CTGF* or upregulation of antifibrotic genes such as *TGIFs* and *SMAD7*.^{37–39} Additionally, HDACis have been shown to inhibit proinflammatory cytokine production and have an anti-inflammatory effect in the disease

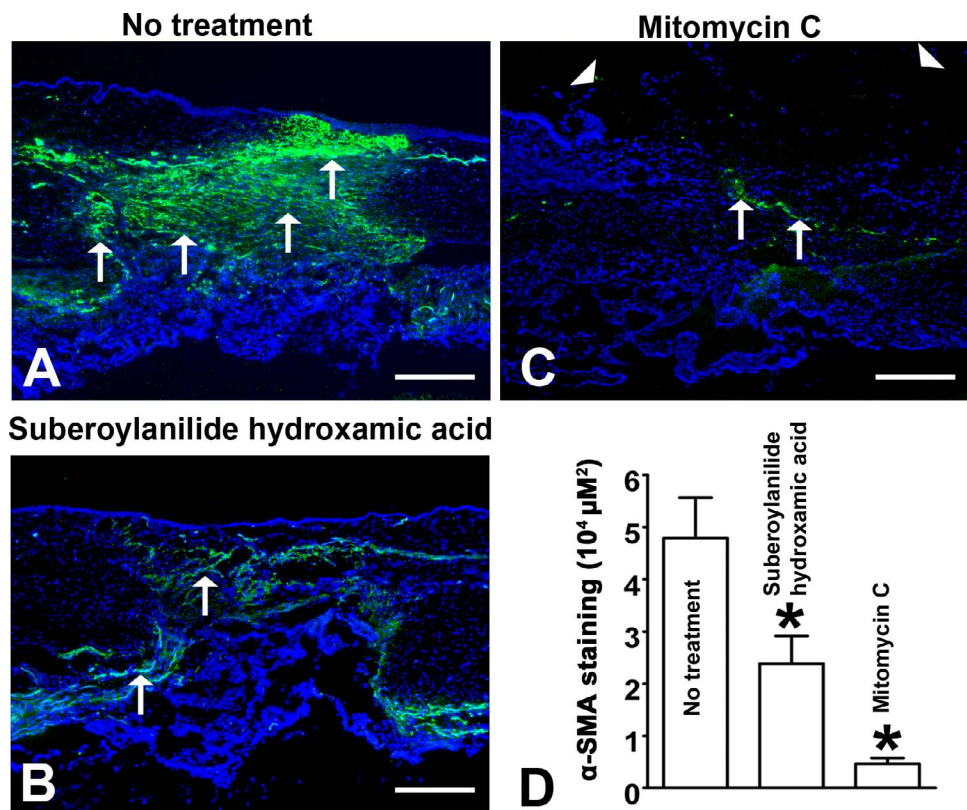


FIGURE 8. Suberoylanilide hydroxamic acid reduces myofibroblast conversion at the site of GFS. Representative images of rabbit ocular tissue sections of the site of sclerotomy showing immunofluorescence staining for α SMA (a myofibroblast marker) in no-treatment control (A), SAHA-treated (B), and MMC-treated (C). Nuclei are stained blue, and α SMA is stained green (arrows). Scale bar: 200 μ m. Graph (D) shows a significant ($*P < 0.01$) decrease in the α SMA-stained area in the SAHA- and MMC-treated rabbit tissues. Arrowhead shows discontinuous and highly sparse DAPI nuclear staining of the conjunctival epithelium in the MMC-treated rabbit tissue sections.

models of inflammatory bowel diseases, multiple sclerosis, and systemic lupus erythematosus.^{40–43} All of these biologic effects of HDACis may have collectively contributed to the observed antifibrotic effect of SAHA in the present study. At present, four HDACis are being tested in clinical trials. However, SAHA was selected for this study because it is the only FDA-approved HDACi in clinical use.

Wound healing is a well-orchestrated event that involves local and recruited progenitor and differentiated cells, growth factors and cytokines, ECM, and relevant enzymes that modify molecular components of the matrix.⁴⁴ Due to the high metabolic activity at the wound site, there is an increasing demand for oxygen and nutrients. Angiogenesis is crucial for wound healing, which supports new tissue growth by allowing adequate distribution of oxygen and nutrients for new tissues to sustain its metabolic needs. It progressively proceeds by sprouting and elongating new capillaries from the blood vessels of the intact tissues around the wound. Fibroblasts are attracted into the wounds and within the wound bed, to produce collagen as well as glycosaminoglycans and proteoglycans, which are major components of the ECM. Following robust proliferation and ECM synthesis, wound healing should stop when a tissue gap is filled. In addition, regression of many of the newly formed capillaries occurs so that vascular density of the wound returns to normal. In some cases, proliferation proceeds longer than needed, leading to elevated scars or even scars whose tissue tends to overgrow. The fibroblast is considered the pivotal cell in pathologic scarring because of its role in matrix deposition and remodeling, and HDACi showed suppression of neovascularization through alteration of genes directly involved in angiogenesis.⁴⁵

Wound healing after GFS involves activation and migration of conjunctival and tenon's capsule fibroblasts to the sclerotomy site, followed by their differentiation into myofibroblasts.^{4–7,16,17} Myofibroblasts are highly contractile and metabolically active cells, causing wound closure by direct contraction and excessive ECM deposition. In the present study, SAHA-treated eyes showed significantly less staining for activated fibroblasts and myofibroblasts in the sclera and conjunctiva surrounding the surgery site. These observations suggest that SAHA attenuates post GFS scarring, possibly through inhibition of fibroblast migration and activation as well as attenuation of myofibroblast formation. These results are supported by the previous studies from our lab showing that SAHA is capable of inhibiting differentiation of cultured rabbit, equine, canine, and human corneal fibroblasts to myofibroblasts.^{30–32} Furthermore, in the earlier studies a 50- μ M or higher dose of SAHA did not decrease cellular viability of cultured corneal fibroblasts.³⁰ Therefore, we speculate that in the present study SAHA did not cause any cytotoxicity to tenon or conjunctival fibroblasts. Lack of inflammation, corneal edema, opacity, endophthalmitis, or cataract formation in SAHA-treated rabbit eyes supports this assumption as well. Studies are underway to test the effect of SAHA on cultured tenon and conjunctival fibroblasts. The lack of cytotoxic effect of SAHA is in stark contrast to currently used drugs MMC or 5-fluorouracil, which presumably inhibit GFS by causing myofibroblast cell death. The nonselective cytotoxic effect of these drugs accounts for the potentially sight-threatening side effects,^{11–15} whereas SAHA appears to inhibit myofibroblast formation while preserving cell viability.

Route of administration, application frequency, and dosage are the three critical determinants of drug efficacy. Previous studies have shown that drug application before sclerostomy minimizes drug spillage into the anterior chamber, which translates to less ciliary body toxicity.⁴⁶ Therefore, we preferred to choose preoperative subconjunctival application of SAHA instead of intraoperative topical application. A one-time intraoperative application of either MMC or 5-fluorouracil during GFS is standard practice in clinical setting.⁸⁻¹⁰ In this study, our decision to administer one SAHA application was tailored to reflect this current clinical practice. Suberoylanilide hydroxamic acid has a short plasma half-life, but based on the data at hand, one-time SAHA application seems potent enough to improve GFS outcome. There is no simple and apparent explanation for these observations. Surgical trauma unfolds a cascade of interrelated events leading to a vicious cycle of excessive wound healing. It is possible that a single SAHA application potentially inhibits these early events and can block the entire fibrotic cascade. Alternatively, SAHA may have some local tissue binding to show an extended release profile. It is also possible that the gene transcription changes induced by a single SAHA dose may last for a few days, which can counter the ongoing fibrotic process. Finally, we acknowledge the few limitations of this study. The present study was terminated at 14 days because wound healing in the rabbit model of GFS is aggressive and leads to bleb failure within 7 to 10 days in untreated animals. However, longer duration and repeat dose studies may be required for the future bench-to-bedside translation of SAHA. Secondly, there was a trend toward lower IOPs in the SAHA-treated groups, but the results were not statistically significant. Intraocular pressure is not considered a reliable indicator in the rabbit model because of the partial wound closure by the aggressive wound healing.⁴⁷ Also, preoperative IOP values are normal in this model, and any further decrease in IOP is neutralized by a physiologic counter-regulatory mechanisms. In summary, this study demonstrates that HDAC inhibition is an attractive pharmacologic target to modulate GFS wound healing, and SAHA, an HDACi, can be a useful adjunct to improve the GFS outcome.

Acknowledgments

Supported by the University of Missouri Ruth M. Kraeuchi Missouri Endowment of Ophthalmology fund (RRM), an American Glaucoma Foundation grant (MR), Veteran Health Affairs Merit Grant 5I01BX000357-05 (RRM), and National Eye Institute Grant 2R01EY017294-06 (RRM).

Disclosure: **A. Sharma**, None; **G. Anumanthan**, None; **M. Reyes**, None; **H. Chen**, None; **J.W. Brubaker**, None; **S. Siddiqui**, None; **S. Gupta**, None; **F.G. Rieger**, None; **R.R. Mohan**, None

References

- Resnikoff S, Pascolini D, Etya'ale D, et al. Global data on visual impairment in the year 2002. *Bull World Health Organ.* 2004; 82:844-851.
- Shoemaker, JA. *Vision Problems in the United States: Prevalence of Adult Vision Impairment and Age-Related Eye Disease in America.* Baltimore, MD: Prevent Blindness America; 2002.
- Crawley L, Zamir SM, Cordeiro MF, Guo L. Clinical options for the reduction of elevated intraocular pressure. *Ophthalmol Eye Dis.* 2012;4:43-64.
- Seibold LK, Sherwood MB, Kahook MY. Wound modulation after filtration surgery. *Surv Ophthalmol.* 2012;57:530-550.
- Georgoulas S, Dahlmann-Noor A, Brocchini S, Khaw PT. Modulation of wound healing during and after glaucoma surgery. *Prog Brain Res.* 2008;173:237-254.
- Chang MR, Cheng Q, Lee DA. Basic science and clinical aspects of wound healing in glaucoma filtering surgery. *J Ocul Pharmacol Ther.* 1998;14:75-95.
- Khaw PT, Chang L, Wong TT, Mead A, Daniels JT, Cordeiro MF. Modulation of wound healing after glaucoma surgery. *Curr Opin Ophthalmol.* 2001;12:143-148.
- Green E, Wilkins M, Bunce C, Wormald R. 5-Fluorouracil for glaucoma surgery. *Cochrane Database Syst Rev.* 2014;2: CD001132.
- De Fendi LI, Arruda GV, Scott IU, Paula JS. MMC versus 5-fluorouracil as an adjunctive treatment for trabeculectomy: a meta-analysis of randomized clinical trials. *Clin Experiment Ophthalmol.* 2013;41:798-806.
- Wilkins M, Indar A, Wormald R. Intra-operative MMC for glaucoma surgery. *Cochrane Database Syst Rev.* 2001;1: CD002897.
- DeBry PW, Perkins TW, Heatley G, et al. Incidence of late-onset bleb-related complications following trabeculectomy with mitomycin. *Arch Ophthalmol.* 2002;120:297-300.
- Muckley ED, Lehrer RA. Late-onset blebitis/endophthalmitis: incidence and outcomes with MMC. *Optom Vis Sci.* 2004;81: 499-504.
- Anand N, Arora S, Clowes M. MMC augmented glaucoma surgery: evolution of filtering bleb avascularity, transconjunctival oozing, and leaks. *Br J Ophthalmol.* 2006;90:175-180.
- Susanna R Jr, Takahashi W, Nicoletta M. Late bleb leakage after trabeculectomy with 5-fluorouracil or MMC. *Can J Ophthalmol.* 1996;31:296-300.
- Palanca-Capistrano AM, Hall J, Cantor LB, Morgan L, Hoop J, WuDunn D. Long-term outcomes of intraoperative 5-fluorouracil versus intraoperative MMC in primary trabeculectomy surgery. *Ophthalmology.* 2009;116:185-190.
- Chang L, Crowston JG, Cordeiro MF, Akbar AN, Khaw PT. The role of the immune system in conjunctival wound healing after glaucoma surgery. *Surv Ophthalmol.* 2000;45:49-68.
- Gillies MC, Su T. Cytokines, fibrosis and the failure of glaucoma filtration surgery. *Aust N Z J Ophthalmol.* 1991;19:299-304.
- Yamanaka O, Kitano-Izutani A, Tomoyose K, Reinach PS. Pathobiology of wound healing after glaucoma filtration surgery. *BMC Ophthalmol.* 2015;157:19-25.
- Verdone L, Caserta M, Di Mauro E. Role of histone acetylation in the control of gene expression. *Biochem Cell Biol.* 2005;83: 344-353.
- An W. Histone acetylation and methylation: combinatorial players for transcriptional regulation. *Subcell Biochem.* 2007; 41:351-369.
- Pang M, Zhuang S. Histone deacetylase: a potential therapeutic target for fibrotic disorders. *J Pharmacol Exp Ther.* 2010;335: 266-272.
- Van Beneden K, Mannaerts I, Pauwels M, Van den Branden C, van Grunsven LA. HDAC inhibitors in experimental liver and kidney fibrosis. *Fibrogenesis Tissue Repair.* 2013;6:1.
- Wang Z, Chen C, Finger SN, et al. Suberoylanilide hydroxamic acid: a potential epigenetic therapeutic agent for lung fibrosis? *Eur Respir J.* 2009;34:145-155.
- Sanders YY, Hagood JS, Liu H, Zhang W, Ambalavanan N, Thannickal VJ. Histone deacetylase inhibition promotes fibroblast apoptosis and ameliorates pulmonary fibrosis in mice. *Eur Respir J.* 2014;43:1448-1458.
- Kao YH, Liou JP, Chung CC, et al. Histone deacetylase inhibition improved cardiac functions with direct antifibrotic activity in heart failure. *Int J Cardiol.* 2013;168:4178-4183.
- Iyer A, Fenning A, Lim J, et al. Antifibrotic activity of an inhibitor of histone deacetylases in DOCA-salt hypertensive rats. *Br J Pharmacol.* 2010;159:1408-1417.

27. Tao H, Shi KH, Yang JJ, Huang C, Zhan HY, Li J. Histone deacetylases in cardiac fibrosis: current perspectives for therapy. *Cell Signal*. 2014;26:521-527.
28. Tang J, Yan H, Zhuang S. Histone deacetylases as targets for treatment of multiple diseases. *Clin Sci (Lond)*. 2013;124:651-662.
29. Sharma A, Mehan MM, Sinha S, Cowden JW, Mohan RR. Trichostatin A inhibits corneal haze in vitro and in vivo. *Invest Ophthalmol Vis Sci*. 2009;50:2695-2701.
30. Tandon A, Tovey JC, Waggoner MR, et al. SAHA: a potent agent to prevent and treat laser-induced corneal haze. *J Refract Surg*. 2012;28:285-290.
31. Donnelly KS, Giuliano EA, Sharm A, Mohan RR. Suberoylanilide hydroxamic acid (SAHA): its role on equine corneal fibrosis and matrix metalloproteinase activity. *Vet Ophthalmol*. 2014;17(suppl 1):61-68.
32. Bosiack AP, Giuliano EA, Gupta R, Mohan RR. Efficacy and safety of suberoylanilide hydroxamic acid (SAHA) in the treatment of canine corneal fibrosis. *Vet Ophthalmol*. 2012;15:307-314.
33. Takeuchi K, Nakazawa M, Ebara Y, et al. Inhibitory effects of trehalose on fibroblast proliferation and implications for ocular surgery. *Exp Eye Res*. 2010;91:567-577.
34. Finnin MS, Donigian JR, Cohen A, et al. Structures of a histone deacetylase homologue bound to the TSA and SAHA inhibitors. *Nature (London)*. 1999;401:188-193.
35. Park KC, Park JH, Jeon JY, et al. A new histone deacetylase inhibitor improves liver fibrosis in BDL rats through suppression of hepatic stellate cells. *Br J Pharmacol*. 2014;171:4820-4830.
36. Beneden K, Mannaerts I, Pauwels M, Van den Branden C, van Grunsven LA. HDAC inhibitors in experimental liver and kidney fibrosis. *Fibrogenesis Tissue Repair*. 2013;6:1.
37. Komorowsky C, Ocker M, Goppelt-Struebe M. Differential regulation of connective tissue growth factor in renal cells by histone deacetylase inhibitors. *J Cell Mol Med*. 2009;13:2353-2364.
38. Kitano A, Okada Y, Yamanka O, Shirai K, Mohan RR, Saika S. Therapeutic potential of trichostatin A to control inflammatory and fibrogenic disorders of the ocular surface. *Mol Vis*. 2010;31:2964-2973.
39. Sharma A, Sinha NR, Siddiqui S, Mohan RR. Role of 5'TG3'-interacting factors (TGIFs) in Vorinostat (HDAC inhibitor)-mediated Corneal Fibrosis Inhibition. *Mol Vis*. 2015;21:974-984.
40. Felice C, Lewis A, Armuzzi A, Lindsay JO, Silver A. Review article: selective histone deacetylase isoforms as potential therapeutic targets in inflammatory bowel diseases. *Aliment Pharmacol Ther*. 2015;41:26-38.
41. Cantley MD, Haynes DR. Epigenetic regulation of inflammation: progressing from broad acting histone deacetylase (HDAC) inhibitors to targeting specific HDACs. *Inflammopharmacology*. 2013;21:301-307.
42. Shanmugam MK, Sethi G. Role of epigenetics in inflammation-associated diseases. *Subcell Biochem*. 2013;61:627-657.
43. Choo QY, Ho PC, Lin HS. Histone deacetylase inhibitors: new hope for rheumatoid arthritis? *Curr Pharm Des*. 2008;14:803-820.
44. Gurtner GC, Werner S, Barrandon Y, Longaker MT. Wound repair and regeneration. *Nature*. 2008;453:314-321.
45. Bolden JE, Peart MJ, Johnstone RW. Anticancer activities of histone deacetylase inhibitors. *Nat Rev Drug Discov*. 2006;5:769-784.
46. Khaw PT, Jones E, Mireskandari K, Dahlmann A, Cambrey A. Modulating wound healing after glaucoma surgery. *Glaucoma Today*. 2004;2:12-19.
47. Grisanti S, Szurman P, Warga M, et al. Decorin modulates wound healing in experimental glaucoma filtration surgery: a pilot study. *Invest Ophthalmol Vis Sci*. 2005;46:191-196.